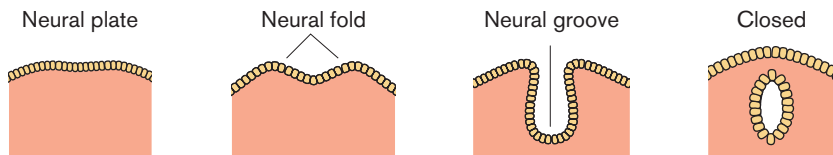
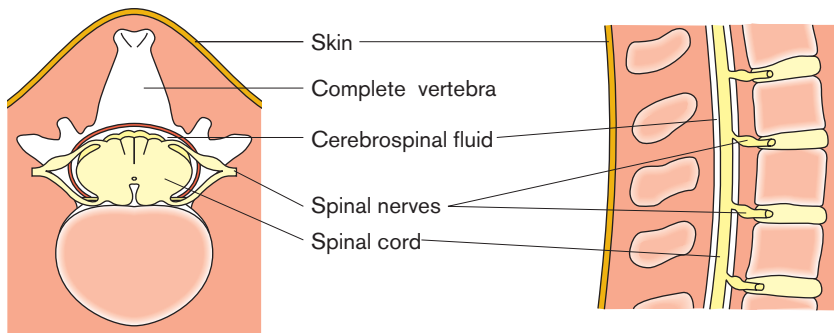


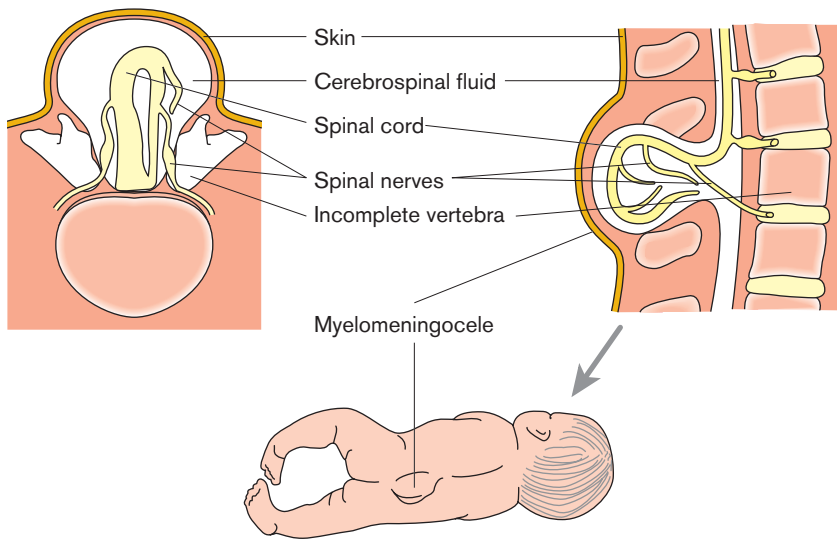
FIGURE 14.2 Normal Development of the Neural Tube, Normal Spine at Birth, and Spina Bifida



(a) Normal embryonic development



(b) Normal spine at birth



(c) Spina bifida